

# Comparing various implant designs and surfaces

## A clinical study

**Authors** Roy Leshem D.M.D.<sup>1</sup>, David Leshem M.D.<sup>2</sup>

### \_Abstract

A clinical study of various types of Hi-Tec Implants (Herzlia, Israel) – uncoated titanium thread implants & push-in cylinder implants, coated with either TPS or Hydroxyapatite (HA) surfaces, used by a surgical team in various surgical procedures. The purpose of the study was to find whether the design or coating of implants has any effect on the success rate and integration of the implant in different procedures. The study did not indicate any statistical significance in the success rate of the different implants in the different types of procedures: simple implantology, sinus lift procedures, bone augmentation and immediate extraction sites.

**Fig. 1a** Alveolar bone height 1 mm to sinus, before extracting second premolar.

**Fig. 1b** 13mm 4.2 thread implant placed with closed technique sinus augmentation.

**Fig. 2a** Alveolar bone height 3 mm to sinus.

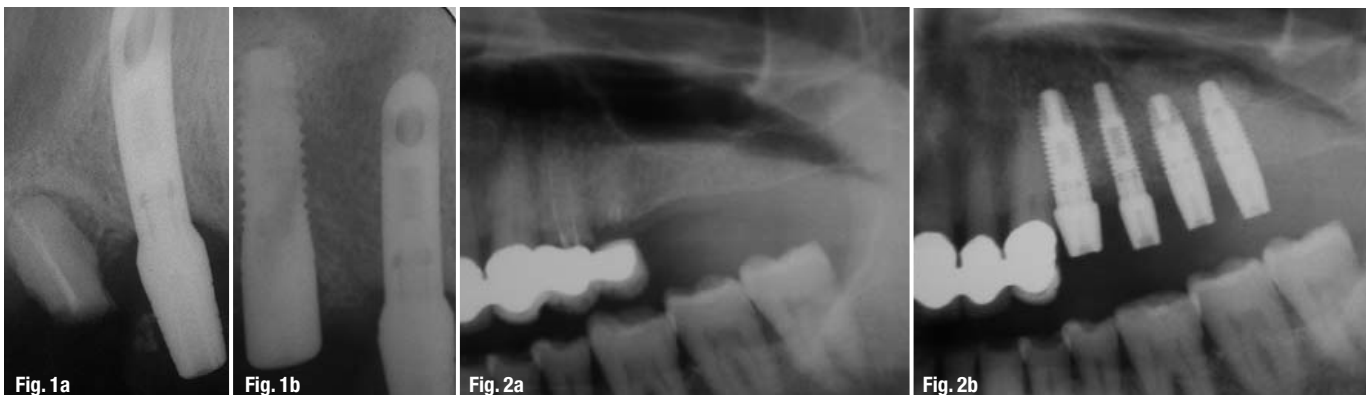**Fig. 2b** 11.5 mm 5.00 thread implants placed with closed technique sinus augmentation

### \_Introduction

Various implant designs and implant coatings are in wide use and success rates are of the various designs and surfaces are well documented. Success rate comparison between HA coated and non coated threaded implants (1, 2) as well

as comparison between HA and TPS coated cylinder implants have been documented (3). Use of implants varies in different procedures, and comparisons between the success rate in different procedures including placing implants immediately in to fresh extraction sites is documented (4, 5, 6) as well as success rate in different locations (7).

The objective of the study was to present the success rate of fixtures of different designs and surfaces used in complex implant procedures, implants placed in internal sinus lift procedures (Figs. 1a–b), implants placed in lateral sinus lift procedures (Figs. 2a–b) bone augmentations, implants placed including grafting of buccal defect (Figs. 3a–d), and implants placed simultaneously with teeth extractions (Figs. 4a–d), all performed by one team. The retrospective study was conducted on patients treated at the Maxillary Facial Dept. of the Meir Hospital, Kfar Saba, ISRAEL and comprised of 144 implants consequently placed over a period of 4 years in 44 patients with partial or complete edentulous. Five



(5) implants failed (3.47%) - two (2) in the maxilla (2.81%) and three (3) in the mandible (4.10%).

## \_Materials and Methods

The study consists of 144 consequently placed 3.50mm Hydroxyapatite Coated cylinder shape Implants (Smooth-Fit, Hi-Tec Implants, Herzlia, Israel).

Titanium Plasma Spray Coated cylinder shape Implants (Smooth-Fit, Hi-Tec Implants, Herzlia, Israel). 3.75 and 5.00 uncoated Self-Tapping Thread Titanium Implants. (Self Thread, Hi-Tec Implants, Herzlia, Israel). The coated fixtures were made of surgical titanium alloy, coated with 50 Microns layer of Hydroxyapatite or titanium plasma spray and have a 1mm polished (uncoated) collar from the neck of the implant. The uncoated thread implants were made of surgical titanium alloy with acid etched surface. Various length implants were used.

The patient underwent routine medical, dental and radiographic assessment (including panoramic radiography) and was evaluated to determine whether the procedure was feasible and if positive, the treatment procedure was planned. Each patient was counseled concerning the nature of the treatment, and a comprehensive consent form was signed.

Surgical placement of the implants was based on the following procedure:

The patient was placed under local or general anesthesia. Depending upon the site of the intended procedure, a mid-crestal, incision was made, and a flap was lifted exposing the underlying bone. An osteotomy was performed with internal irrigated drills using sterile physiological water. The implant was inserted into the prepared site and the flaps were closed by sutures.

Distribution of implants regarding sex and jaw			
Jaw	Female	Male	Total
Maxilla	44	36	80
Mandible	29	35	64
Total	73	71	144

**Tab 1**

Distribution of implants regarding type of edulism & jaw				
Jaw	Complete Edentulous	Multiple missing teeth	Single missing teeth	Total
Maxilla	20	55	5	80
Mandible	30	30	4	64
Total	50	85	9	144

**Tab 2**

Distribution of Implants by Types of Anesthesia			
Anesthetic	General	Local	Total
Maxilla	33	47	80
Mandible	10	54	64

**Tab 3**

During this four year period surgeries were performed on 44 patients: 26 women and 18 men.

Stage II was performed under local anesthetic 3-6 months after Stage I.

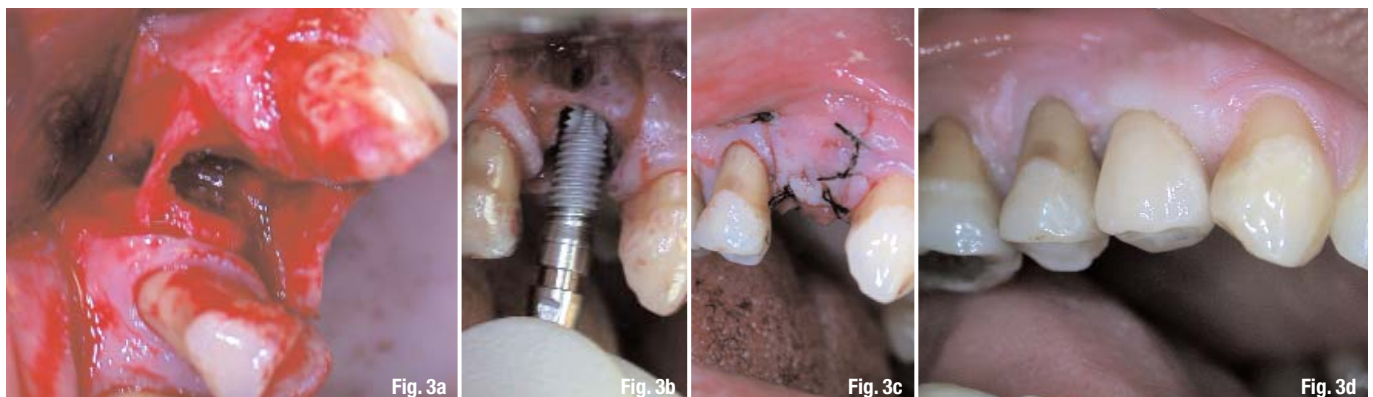
This entailed opening a flap, exposing the cover screw and replacing it with a Titanium 3mm or

**Fig. 3a** Buccal defect connecting to the socket of first premolar with 2.0 mm remaining of buccal wall.

**Fig. 3b** Placing 4.2 mm Tapered Self Thread Implant.

**Fig. 3c** Complete closure after augmentation of buccal defect and socket.

**Fig. 3d** Final restoration with Zirconium Abutment.



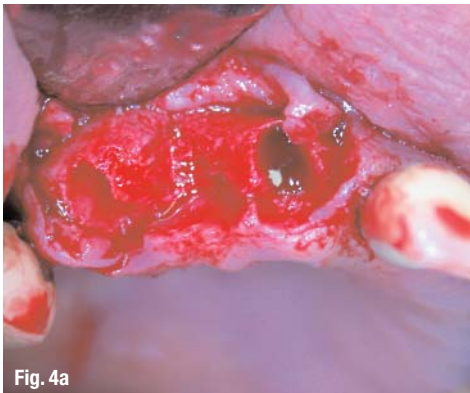


Fig. 4a

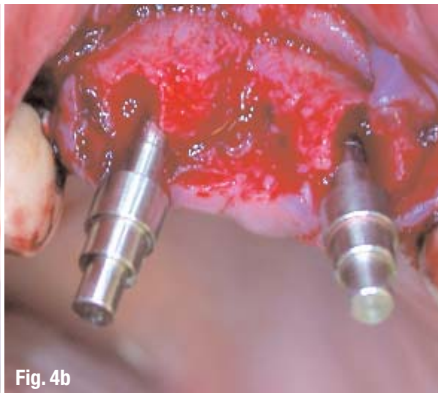


Fig. 4b

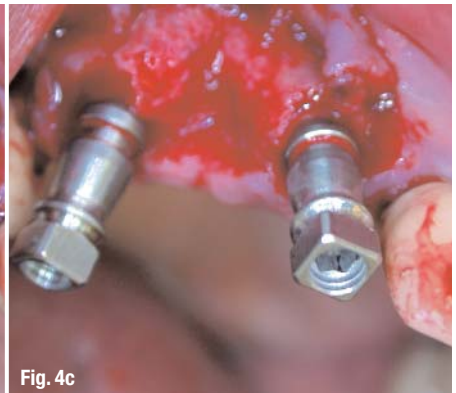


Fig. 4c

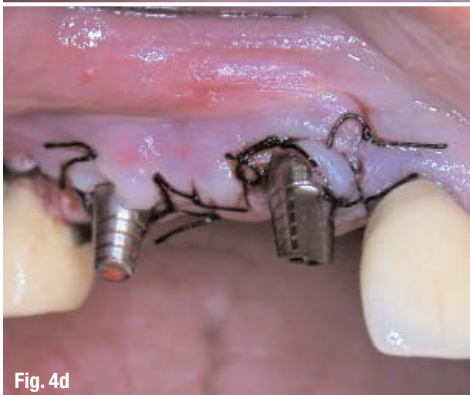

Fig. 4d

**Fig. 4a** Extraction of central incisor and canine.

**Fig. 4b** Paralleling tools in extraction sites.

**Fig. 4c** Two 3.75 mm Tapered Self Thread Implant placed in the fresh sockets.

**Fig. 4d** Abutments placed on implants for immediate provisional restoration.

failures during the follow-up period. Two (2) of the failed implants, 2.81%, were in maxilla and three (3) of the implants, 4.10% in the mandible. Failed implants were present in 5 patients. The distribution of the failed implants regarding sex, jaw type, presented in the following table.

Two (2) of the failing implants were identified and removed during Surgical Stage II and one (1) was lost during preparation of temporary

during Stage I surgery, followed up by using a temporary full denture and commented in protocol at the time of implant placement.

### Results

#### Failures were related to:

One (1) 10mm implant located in poor bone quality of posterior maxilla in an extraction site. One (1) 10mm implant located in posterior mandible. One (1) 13mm implant located in anterior maxilla was placed in a resorbed narrow ridge (2mm). One (1) 13mm implant, placed in the anterior mandible, immediately after the extraction of a contaminated fractured tooth. No specific pattern regarding fixture size could be observed.

All types of implants used in the sinus lift procedures presented a 100% success rate. Four (4) Implants were lost in immediate extraction sites, in resorbed bone sites, and poor bone quality, all lost implants were threaded non-coated implants, statistical significance was not substantiated. Using Pearson's Chi Square test a statistically significant association was found between the three types ( $p=0.04$ )

### Discussion

The results of the study present 3.47% failure rate (5 implants). This is a most favorable result taking into consideration that many of the implants were placed in most unfavorable sites including those with bone defects, unhealed bone extraction sites, sinus lift procedures, bone grafting sites, ridge augmentation and implants placed in extremely narrow ridges.(4,5,6) Implants lost were correlated to the posterior zone due to poorer bone quality (7), narrow ridge and other unfavorable conditions. Posterior maxilla and mandible bone structure is less condensed and therefore the ability of firm osseointegration of the implant is reduced.

Placing implants in poor quality bone in posterior areas and sites with complications increase

restoration. Two (2) of the lost implants, posterior maxilla and posterior mandible, were 10mm long. Three (3) of the lost implants (anterior maxilla and anterior mandible) were 13mm long.

One (1) of the failed implants (anterior maxilla) was placed in the site of bone augmentation and associated with a jaw splitting procedure

Distribution of Implant Length					
	8mm	10mm	13mm	16mm	Total
HA Smooth Fit	0	0	3	4	17
TPS Smooth Fit	0	12	33	18	63
Self Thread	0	22	42	0	64

Tab 4

the risk failure rate. It is even more crucial when the bone is not able to provide initial stability for implants or if the preparation has a fractured wall on one side or more. No considerable difference was noticed in the success rate when the implant placement was combined with bone grafting or bone grafting with sinus lifting.

Implant sites must therefore be evaluated prior to surgery and high risk sites should be bone grafted prior to inserting the implant in order to reduce the occurrence of early and late failures. Naturally should the necessity arise, the surgeon must be skilled in all the different procedures. One fixture that was considered successful during Stage II was found to be mobile during abutment connection. This raises the theory that in poor bone quality, opening and tightening of the healing screw can damage newly formed bone which will consequently resorb and lead to implant mobility.

The study did not find any statistical correlation between the success rates of different procedures to the types of implants used.

## References

A comparison of hydroxyapatite (HA) – Coated threaded, HA – coated cylindric, and titanium threaded endosseous dental implants. Jeffcoat MK, et al. Int J Oral Maxillofac Implants. 2003 May-Jun;18(3):406-10.

A comparison of hydroxyapatite-coated Micro-Vent and pure titanium Swede-Vent implants. Evian CI. Int J Oral Maxillofac Implants. 1996 Sep-Oct;11(5):639-44.

A 5-year comparison of hydroxyapatite-coated titanium plasma-sprayed and titanium plasma-sprayed cylinder dental implants. Jones JD, et al. Oral Surg Oral Med Oral Pathol Oral Radiol Endod. 1999 Jun;87(6):649-52

Immediate or early placement of implants following tooth extraction: review of biologic basis, clinical procedures, and outcomes. Chen ST, Wilson TG Jr, Hämmerle CH. Int J Oral Maxillofac Implants. 2004;19 Suppl:12-25.

Survival of immediately provisionalized dental implants placed immediately into fresh extraction sockets. Schwartz-Arad D, Laviv A, Levin L. J Periodontol. 2007 Feb;78(2):219-23.

Placement of hydroxyapatite-coated implants into fresh or recent extraction sites. Raymond AY. Dental Clinics of North America. 1992; Jan;36(1):97-115.

Implant zones of the jaws: implant location and related success rate. Tolstunov L. J Oral Implantol. 2007;33(4):211-20.

### Distribution of implant placement combined with bone grafting or sinus lift

	Self Thread	TPS SmoothFit	HA Smooth	Fit Total
Bone graft	26	9	1	46
Sinus lift	6	22	7	35
Total	32	31	18	81

Tab 5

### Distribution of implants placed in immediate extraction site

Self Thread	TPS Smooth Fit	HA Smooth Fit
16	4	0

Tab 6

### Distribution of failed implant with regard to jaw, sex & location

Jaw Type	Female	Male	Posterior	Anterior
Maxilla	2	0	2	0
Mandible	2	1	1	2
Total	4	1	3	2

Tab 7

### Distribution of lengths of failed implants

	10 mm	12 mm	16 mm	Total
TPS Smooth Fit 3.5	0	0	0	0
HA Smooth Fit 3.5	0	0	0	0
Self Thread 3.75	1	3	0	4
Self Thread 5.00	1	0	0	1
Total	2	3	0	5

Tab 8

### \_contact

### implants

#### Dr Roy Leshem

1 Maskitstreet  
Herzlia, Israel  
E-mail: hitecimp@netvision.net.il

<sup>1</sup>Private practice, Herzlia, Israel

<sup>2</sup>Head of Pediatric & Craniofacial Plastic Surgery, The Tel Aviv Sourasky Medical Center, Israel.