

Minimally Invasive Antral Membrane Balloon Elevation – Results of a Multicenter Registry

Efraim Kfir, DMD;* Moshe Goldstein, DMD;† Israel Yerushalmi, DMD;‡ Ronen Rafaelov, DMD;§ Ziv Mazor, DMD;|| Vered Kfir, DMD;¶ Edo Kaluski, MD, FACC, FESC, FSCAI#

ABSTRACT

Background and Purpose: Frequently, the posterior maxilla lacks sufficient bone mass to support dental implants. This multiphysician registry assessed the feasibility and safety of minimally invasive antral membrane balloon elevation (MIAMBE), followed by bone augmentation and implant fixation.

Materials and Methods: One hundred twelve consecutive patients were referred for MIAMBE. Following pre-procedural assessment and informed consent, patients underwent alveolar crest exposure, and 3 mm osteotomy followed by MIAMBE. Platelet-rich fibrin and bone substitutes were injected under the antral membrane; implant placement and primary closure were executed at the same sitting. Implant loading was carried out 6 to 9 months later.

Results: One hundred nine (97.3%) patients successfully concluded the initial procedure. Three patients had membrane tear requiring procedure abortion. One case of infection was documented at 4 weeks. Procedure time was 58 ± 23 minutes. Incremental bone height consistently exceeded 10 mm, and implant survival of 95% was observed at 6 to 9 months.

Conclusion: MIAMBE can be applied to all patients in need of posterior maxilla bone augmentation with high procedural success, low complication rate, and satisfactory bone augmentation and implant survival. As it is minimally invasive and associated with minimal discomfort, MIAMBE should be an alternative to the currently employed methods of maxillary bone augmentation.

KEY WORDS: antral membrane, bone augmentation, dental implants, maxillary sinus, posterior maxillary implants

INTRODUCTION

Patients with an edentulous posterior maxillary segment frequently lack adequate bone mass to support dental implants.¹ The challenge of bone augmentation of this segment has been traditionally addressed by two

approaches: (1) lateral maxillary window (“hinge osteotomy”) and (2) the “osteotome technique,”² also called bone-added osteotome sinus floor elevation (BAOSFE). The latter strategy yields modest bone-height increments, hence is not suitable for patients with markedly reduced initial bone height.³ BAOSFE can be complicated by membrane perforation and tear,⁴ which can be somewhat reduced with expert technique and dedicated instrumentation.⁵ The lateral maxillary window offers average implant survival of 91.8% (ranging from 61.7 to 100%).⁶ This method suffers from considerable shortcomings, including procedure complications (membrane tear, bleeding, infection, nerve laceration, and sinus obstruction), peri-procedural swelling and discomfort, and relative contraindications (sinus convolution septum or narrow sinus and previous sinus surgery). Lateral maxillary window also requires considerable surgical skills, equipment, and time. Lateral bone fenestration⁷ suffers from similar shortcomings as lateral maxillary window. Minimally

*Dental Clinic, Petah-Tikva, Israel; †Department of Periodontology, Faculty of Dental Medicine, The Hadassah-Hebrew University Medical Center, Jerusalem, Israel; ‡Dental Clinic, Ramat Gan, Israel; §Dental Clinic, Tel-Aviv, Israel; ||Periodontology and Implant Dentistry Clinic, Ra’anana, Israel; ¶Dental Clinic, Kupat Holim Clalit (Remez), Rehovot, Israel; #director, Cardiac Catheterization Laboratory and Invasive Cardiology, University Hospital, University of Medicine and Dentistry, Newark, NJ, USA

Reprint requests: Dr. Edo Kaluski, Invasive Cardiology and Cardiac Catheterization Laboratories, University Hospital, University of Medicine and Dentistry of New Jersey, 185 South Orange Avenue, MSB I-538, Newark, NJ 07103, USA; e-mail: ekaluski@gmail.com; kalusked@umdnj.edu

© 2009, Copyright the Authors
Journal Compilation © 2009, Wiley Periodicals, Inc.

DOI 10.1111/j.1708-8208.2009.00213.x

invasive antral membrane balloon elevation (MIAMBE) is a modification of the BAOSFE method in which antral membrane elevation is executed via the osteotomy site (of ≤ 3.5 mm) using a dedicated balloon. Former reports involved a single-center experience using non-dedicated equipment⁸ and prototype kits.⁹ This manuscript summarizes the initial MIAMBE multicenter registry employing commercial dedicated kits.

MATERIALS AND METHODS

Patients

This registry included all consecutive patients referred because of edentulous posterior maxillary segment and lack of sufficient bone mass to support implants. These patients were referred to MIAMBE-trained dentists who enrolled in this registry, and were the third cohort treated with this modification of the osteotome technique.

Inclusion criteria included:

1. Planned implants because of edentulous posterior maxilla segment
2. Initial bone height ≤ 6 mm
3. Consensus between the referring physician and the operator that the bone quality cannot support implants without augmentation
4. The patient willing to sign an informed consent

No patients were excluded from this protocol.

Materials

1. MIAMBE balloon harboring device (MIAMBE, Netanya, Israel) – This is a stainless steel tube that connects on its proximal end to the dedicated inflation syringe, and has a screw-in mechanism on its distal portion, which secures the device into the osteotomy site (Figure 1). The single-use balloon is concealed in the distal end until it is inflated with diluted contrast (Figure 2)
2. Dedicated “MIAMBE kit” including bone graft injector, osteotome, screw tap, and a suction device (MIAMBE)
3. Coronary angioplasty inflation syringe (Merit Medical, Galway, Ireland) – filled with diluted contrast material (Ultravist 300, Schering AG, Berlin, Germany)
4. Autologous platelet-rich fibrin (PRF), which was obtained by drawing 40 to 80 mL of patients’ blood.



Figure 1 Balloon harboring device with Holtem stoppers of 1, 2, and 4 mm (A), balloon harboring end (B), and inflator end (C).

Blood was divided into 4 to 8 test tubes and subjected to centrifugation at 2,700 rpm. After being spun for 10 minutes, the PRF clot was removed from the test tube by forceps and placed in a Petri dish

5. Synthetic bone graft (Mineross, Biohorizons, Birmingham, AL, USA)
6. Autogenous bone collected during drilling by bone filter and bone particles from the tuberosity collected with rongeur (Stoma, Emmingen-Liptingen, Germany)
7. Fisiograft gel (Ghimas, Caslecchio de Reno, Italy)

Study Protocol

Pre-procedural computed tomography and panoramic and periapical radiographs were used to assess mucosa thickness and pathology, bone height and thickness, sinus structure, and major blood vessels. Patients received a verbal explanation accompanied by an audio-visual presentation regarding the procedure and signed an informed consent.

Pre-procedural nonsteroidal anti-inflammatory agent was prescribed. Augmentin (clavulanate potassium) 875 mg twice daily was initiated 24 hours prior to the procedure.




Figure 2 Silicone balloon during inflation.

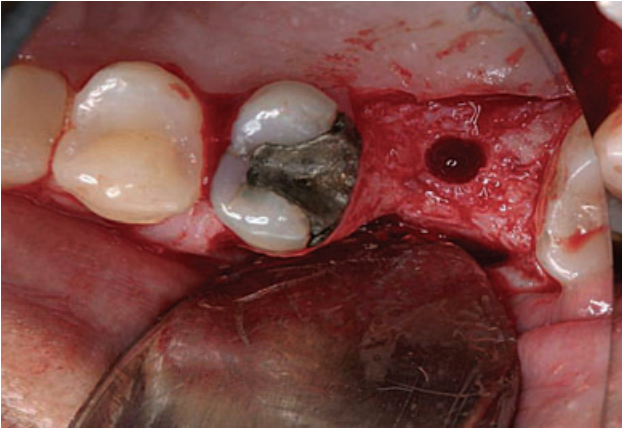


Figure 3 Initial osteotomy.

Nitrous oxide sedation and local anesthesia (infiltration of posterior and middle superior alveolar nerve and greater palatine nerve) were performed using Ubistesin 4% (3M ESPE Dental, Seefeld, Germany). To obtain PRF, 40 to 80 mL of patient's blood was drawn by venous puncture and processed.

Under local anesthesia, horizontal full-thickness flap with palatal bias (to preserve keratinized tissue) was followed by two small vertical incisions to expose the alveolar crest. After drilling depth was determined according to computed tomography scan measurements, pilot drilling (using a 2 mm diameter drill) at the center of the alveolar crest was carried out up to 1 to 2 mm below the sinus floor (Figure 3).

The osteotomy was enlarged from 2 to 2.9 mm with the dedicated osteotome (Figure 4A). Bone graft material was injected into the osteotomy, and subsequently

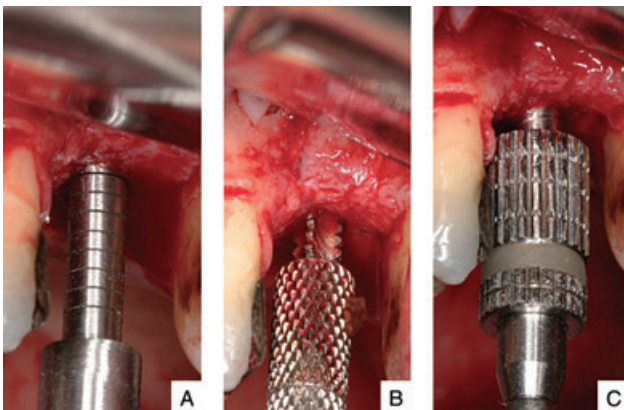


Figure 4 Osteotome (A), screw tap (B), and balloon harboring device (C) in osteotomy.

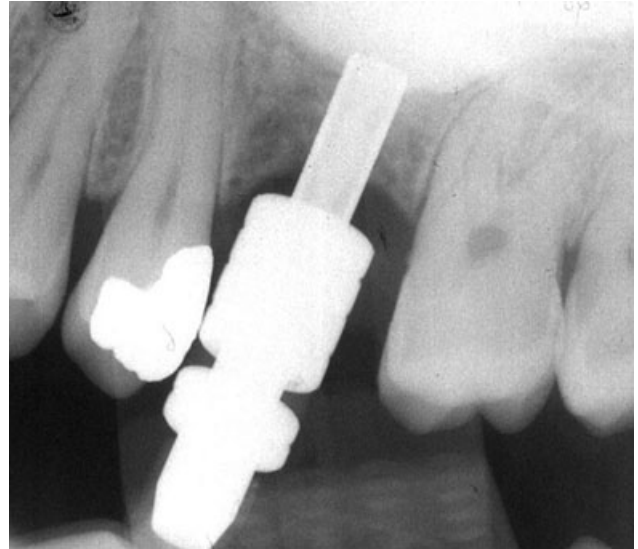


Figure 5 Periapical radiograph of balloon harboring device during inflation.

the sinus floor was gently fractured (penetration depth is controlled by adjusting the length of Teflon stoppers of the osteotome). After removing the osteotome, the membrane integrity was assessed (by Valsalva maneuver). Bone graft material was injected again, and the screw tap was tapped into the osteotomy 2 mm beyond the sinus floor (Figure 4B).

After screw-tap removal and sinus membrane integrity evaluation, the metal sleeve of the balloon harboring device was inserted into the osteotomy 1 mm beyond the sinus floor (Figure 4C). The balloon was inflated slowly with the barometric inflator up to two atmospheres. Once the balloon emerged from the metal sleeve and expanded underneath the sinus membrane, the pressure dropped down to 0.5 atmospheres. Subsequently, the balloon is inflated with progressively higher volume of contrast fluid. The balloon inflation and membrane elevation are evaluated by sequential periapical X-rays (Figure 5). Once the desired elevation (usually >10 mm) was obtained, the balloon was left inflated ≥ 5 minutes (to reduce the sinus membrane recoil). Then the balloon was deflated and removed. The membrane integrity was reassessed by direct visualization and examination with the suction syringe and respiratory movement of blood within the osteotomy.

Via a bone graft injector, a mix of bone substitute (Mineross), PRF, and autologous bone particles (collected by suction filter during drilling and bone from the tuberosity) was injected through the osteotomy

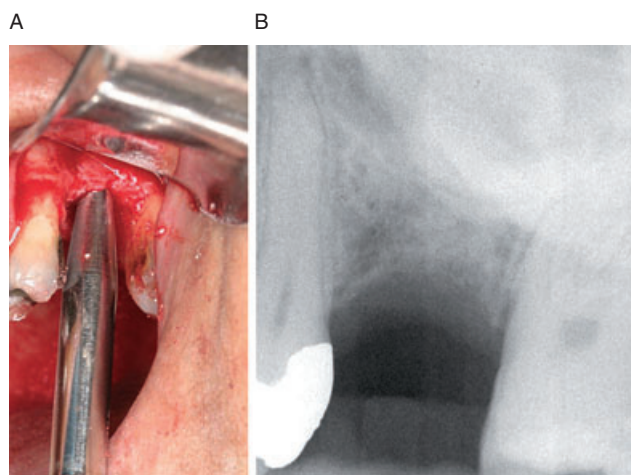


Figure 6 Bone graft injector in osteotomy (A). Periapical radiograph after bone graft injection (B).

underneath the antral membrane (Figure 6, A and B). Bone grafting was followed by implant (3.75–5 mm diameter) placement and primary closure.

Patients were discharged with Ibuprofen 600 mg (single dose) for pain relief and Augmentin 875 mg twice daily for 7 days. Suture removal was executed within 7 days. At 6 months follow-up, computed tomography and periapical radiographs were performed, and prosthetic rehabilitation was initiated 3 weeks after implant exposure.

Study End Points

This registry’s feasibility and efficacy primary end point was a successful conclusion of the initial procedure

(including ≥ 10 mm antral membrane elevation, bone grafting, and implant fixation). Primary safety end point was major complications (including severe bleeding, infection, nerve injury, and prolonged [>7 days] disability). Procedure time, implant failure, and bone height at 6 months were also monitored.

RESULTS

Patients

Between July 2003 and November 2008, 112 patients were referred for the procedure. Mean age was 44.1 ± 12.9 years, 35 (31%) were smokers, and 62 (55%) were females (Figure 7).

Primary End Point: Procedural Success

Initial procedural success was accomplished in 109 (97.3%) patients. Three procedures were aborted because of membrane tear. All three patients have successfully undergone MIAMBE 3 months after the initial failed attempt. Nine patients had micropuncture of the antral membrane; however, in these cases, MIAMBE was executed successfully employing a PRF membrane to close the perforation. In three cases in which the initial bone height was ≤ 1 mm, a decision not to place implants at the initial sitting was made. A single case of infection and oroantral fistula at 4 weeks after sinus augmentation and implant placement requiring implant removal was recorded (the fistula was closed spontaneously after

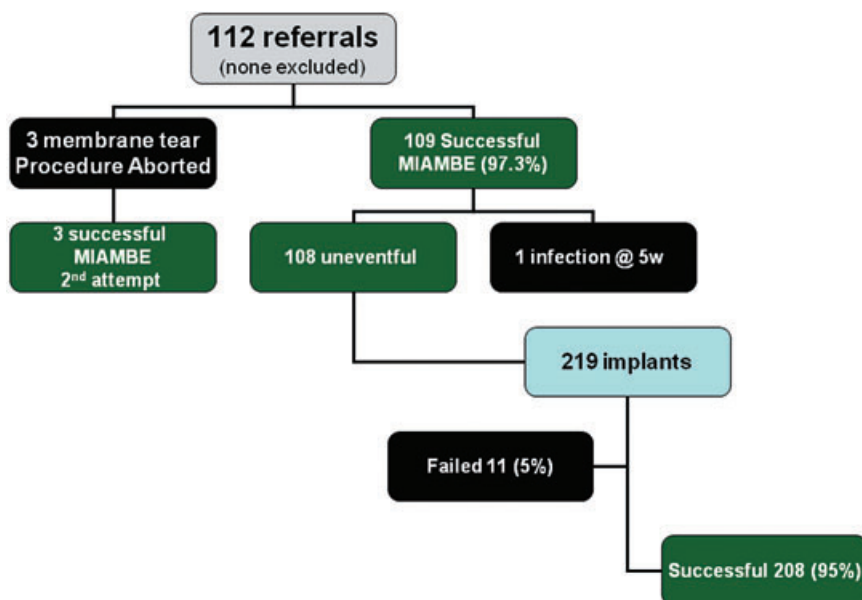


Figure 7 Registry flowchart. MIAMBE = minimally invasive antral membrane balloon elevation.

TABLE 1 Results of 112 Patients Undergoing MIAMBE

	Current Study (n = 112)
Primary procedural success (%)	109 (97.3)
Secondary procedural success (%)	112 (100)
Initial bone height (mm, mean \pm SD)	3.8 \pm 2.1
\leq 2 mm (n, %)	12 (10.7)
2.5 and 3 mm (n, %)	24 (21.4)
3.5 and 4 mm (n, %)	32 (28.5)
4.5 and 5 mm (n, %)	27 (24.1)
5.5 and 6 mm (n, %)	17 (15.2)
6 months bone-height increment (range)	11–18
Number of implants per procedure (mean \pm SD)	1.95 \pm 0.73
Implants/procedure (intention to treat analysis)	
None (n, %)	(2, 1.8)
One implant (n, %)	(26, 23.2)
Two implants (n, %)	(59, 52.6)
Three implants (n, %)	(25, 22.3)
Range of implant diameter (mm)	3.75–5
Range of implant length (mm)	13–17.1
Major complications	Three membrane tear One infection
Procedure time (mean \pm SD)	58 \pm 23
Implant failure at 6 months (%)	11 (5)
Follow in months (mean \pm SD)	13 \pm 6

4 months). No other complications were recorded during or after the procedure.

Secondary End Points

Procedure time was 58 \pm 23 minutes for all operators. Eleven out of 219 implants (5%) failed during the follow-up of \geq 6 months. Patients needed very little medical attention: no patient required additional pain-control medications or medication for swelling alleviation. There were no post-procedural emergency or distress calls. Table 1 shows a summary of the results of the current study.

Demonstrative Cases

We submit two demonstrative cases that emphasize technical aspects of the procedure (Figures 8, A–E, and 9, A–F).

DISCUSSION

This registry supports the former notion that MIAMBE, a minimally invasive, single-sitting procedure of maxillary bone augmentation, and implant placement can be executed by various operators (mostly dentists without extensive surgical skills) with a relatively short learning curve. The procedural goals of this new method were met: initial procedural success of 97.3% and ultimate procedural success of 100% (when second MIAMBE attempts were accounted for). There was only one case of major complication (late infection) in this nonselective, all-inclusive cohort. Although the mean pre-procedural bone height in this series was 3.8 mm, the authors are convinced that there is no minimal bone height required for this procedure. MIAMBE of atrophic (“eggshell”) maxillary bone (like Figure 10) resulted in similar success rates and bone growth as the less diseased maxillas. The registry incorporated numerous cases of septated maxillary sinus (see Figures 8 and 10) and other challenging sinus and periodontal pathology.

The procedure consistently yielded satisfactory bone augmentation, which resulted in an impressive (95%) implant survival at 6 months. The authors acknowledge the fact many pathological or procedural factors affect bone formation and implant survival, and that the methodology of antral membrane elevation may not have any influence on implant survival. However, implant survival was assessed in order to substantiate the fact that implant durability subsequent to MIAMBE is not inferior to any formerly reported series using conventional methods of sinus lift and bone augmentation.

On the physician end, this procedure is highly successful, with a relatively short learning curve, without excessive costs and labor-intensive post-procedural issues. Among the operators, especially the maxillofacial surgeons (who were accustomed to hinge osteotomy) could appreciate the simplicity and trouble-free course of MIAMBE.

On the patient side, this procedure eliminates the complications, discomfort, and disfiguring associated with traditional hinge osteotomy, and may abbreviate the time to implant exposure and functionality. These “patient issues” are probably the major patient-related barriers of more widespread use of implants in the posterior maxillary segment.

Soltan and Smiler⁷ describe antral membrane balloon elevation via a lateral bone fenestration as

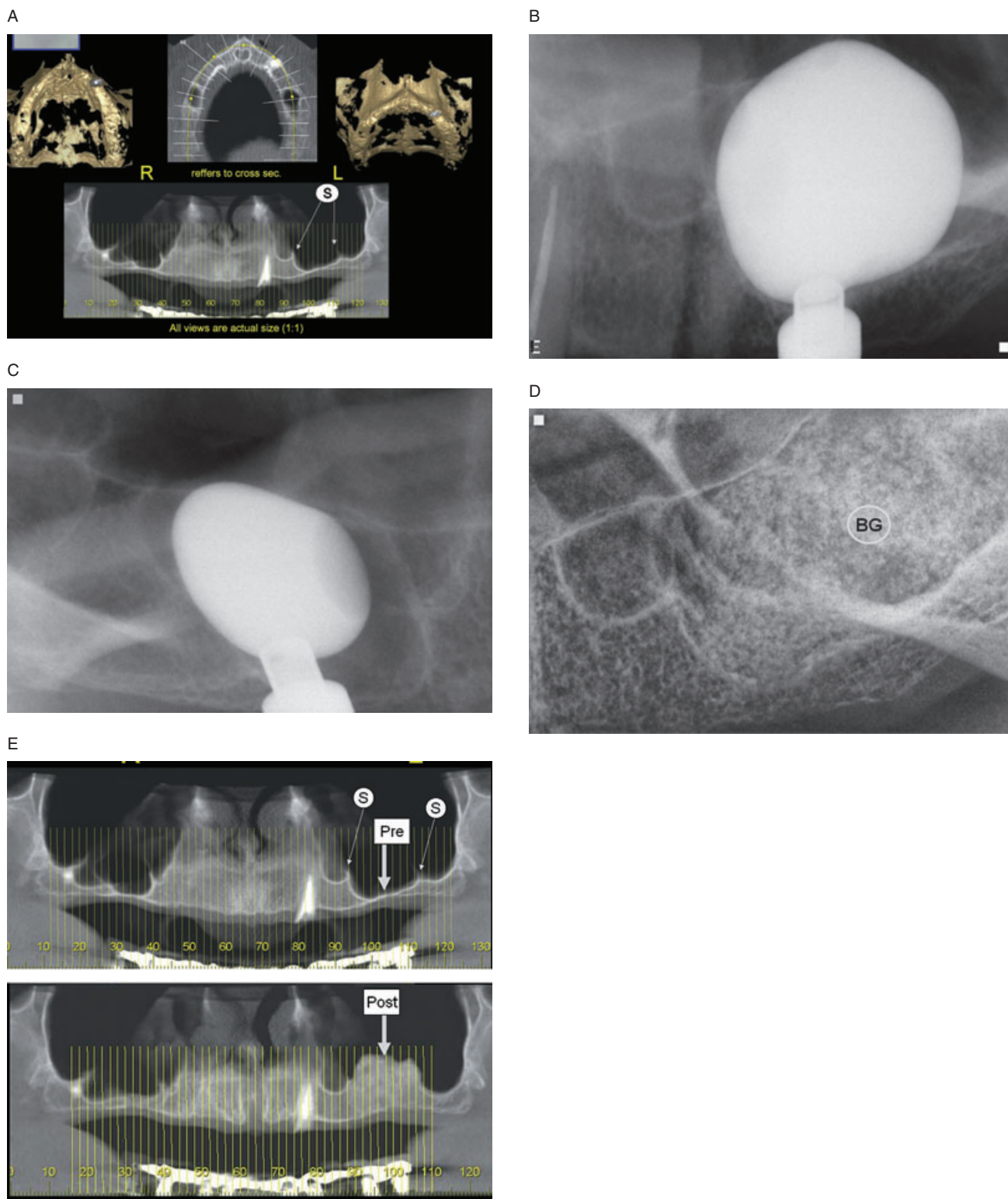


Figure 8 MIAMBE performed in complex pathology (eggshell atrophic maxillary bone and maxillary sinus with 2 septa). *A*, Pre-procedural CT: note bone height is 1 mm and double septum (s). *B*, Medial MIAMBE. *C*, Lateral MIAMBE. *D*, After bone grafting (BG). *E*, Bone height 6 months later.

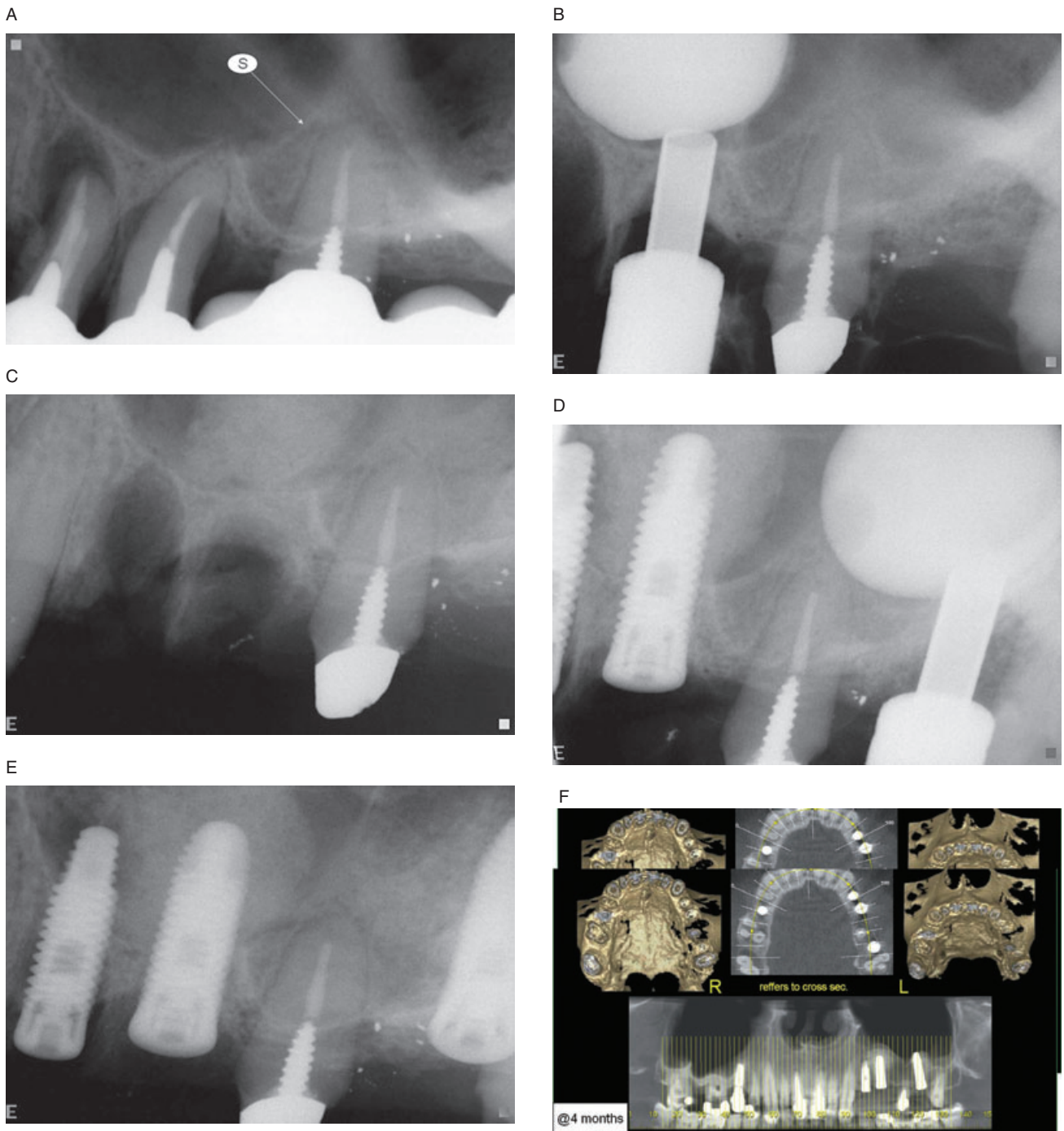


Figure 9 MIAMBE performed immediately after tooth extraction. *A*, Before extraction. Note septum (S). *B*, Medial MIAMBE. *C*, Medial bone grafting. *D*, Lateral MIAMBE. *E*, Lateral bone grafting and implant placement. *F*, Four months after procedure.

somewhat less invasive than conventional hinge osteotomy; however, that approach is not minimally invasive.

The “osteotome technique” (BAOSFE) is truly minimally invasive, but this method is clearly inferior to lateral window approach, if the initial height is ≤ 4 mm.¹⁰ The “osteotome technique,” even when selectively

applied¹¹ and endoscopically controlled, yields modest antral membrane elevation and bone augmentation, requires considerable skills, and may frequently result in membrane tear.³ Although certain single-center trials report exceptional results with the osteotome technique,² a meta-analysis¹² evaluating the “osteotome technique” concluded that “Short-term clinical success/

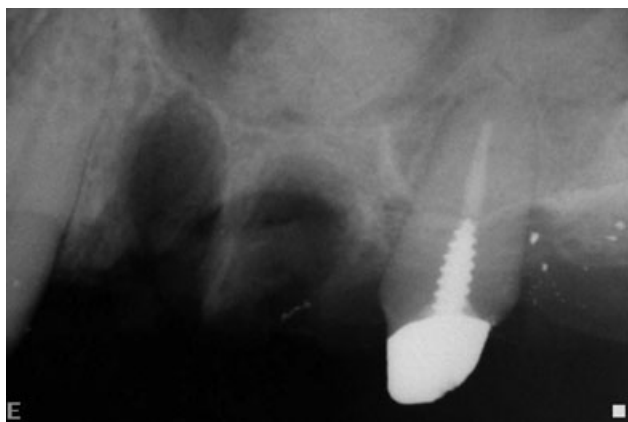

Figure 10 Minimally invasive antral membrane balloon elevation (MIAMBE) performed on atrophic (eggshell) maxilla.

survival of implants placed with an osteotome sinus floor elevation technique seems to be similar to that of implants conventionally placed in the partially edentulous maxilla⁷. These authors implied that randomized-controlled prospective clinical studies are needed to evaluate the long-term outcome of BAOSFE. Other minimally invasive methods, such as the hydraulic sinus condensing technique, reported favorable results in a single-center study¹³ but have never been widely accepted.

Although we have used bone substitute and PRF as part of this study's protocol, in hope to enhance bone augmentation, we do not believe that there are compelling data to substantiate the use of one bone grafting protocol or another. Animal¹⁴ and human¹⁵⁻¹⁷ studies have yielded conflicting results on the beneficial effects of PRF on bone healing and augmentation. It is possible that similar results could be obtained using other filling materials or not using any bone graft material at all.¹⁸

CONCLUSION

MIAMBE appears to carry a high procedural success and very acceptable complication rate. It appears to be a safe and effective way to execute antral membrane elevation and posterior maxillary bone augmentation. On the patient end, the procedure is truly minimally invasive and is associated with only mild discomfort and consistently delivers early functional implants. On the physician end, it appears from this registry that MIAMBE is safe and requires a relatively "short learning curve" even among general dentists engaged in implantology.

REFERENCES

- Garg AK. Augmentation grafting of the maxillary sinus for placement of dental implants: anatomy, physiology, and procedures. *Implant Dent* 1999; 8:36-46.
- Ferrigno N, Laureti M, Fanali S. Dental implants placement in conjunction with osteotome sinus floor elevation: a 12-year life-table analysis from a prospective study on 588 ITI implants. *Clin Oral Implants Res* 2006; 17:194-205.
- Nkenke E, Schlegel A, Schultze-Mosgau S, Neukam FW, Wiltfang J. The endoscopically controlled osteotome sinus floor elevation: a preliminary prospective study. *Int J Oral Maxillofac Implants* 2002; 17:557-566.
- Berengo M, Sivoilella S, Majzoub Z, Cordioli G. Endoscopic evaluation of the bone-added osteotome sinus floor elevation procedure. *Int J Oral Maxillofac Surg* 2004; 33:189-194.
- Toffler M. Staged sinus augmentation using a crestal core elevation procedure and modified osteotomes to minimize membrane perforation. *Pract Proced Aesthet Dent* 2002; 14:767-774.
- Wallace SS, Froum SJ. Effect of maxillary sinus augmentation on the survival of endosseous dental implants. A systematic review. *Ann Periodontol* 2003; 8:328-343.
- Soltan M, Smiler D. Antral membrane balloon elevation. *J Oral Implantol* 2005; 31:85-90.
- Kfir E, Kfir V, Mijiritsky E, Rafaeloff R, Kaluski E. Minimally invasive antral membrane balloon elevation followed by maxillary bone augmentation and implant fixation. *J Oral Implantol* 2006; 32:26-33.
- Kfir E, Kfir V, Eliav E, Kaluski E. Minimally invasive antral membrane balloon elevation: report of 36 procedures. *J Periodontol* 2007; 78:2032-2035.
- Rosen PS, Summers R, Mellado JR, et al. Bone-added osteotome sinus floor elevation technique: multicenter retrospective report of consecutively treated patients. *Int J Oral Maxillofac Implants* 1999; 14:853-858.
- Fugazzotto PA. Augmentation of the posterior maxilla: a proposed hierarchy of treatment selection. *J Periodontol* 2003; 74:1682-1691.
- Emmerich D, Att W, Stappert C. Sinus floor elevation using osteotomes: a systematic review and meta-analysis. *J Periodontol* 2005; 76:1237-1251.
- Chen L, Cha J. An 8-year retrospective study: 1,100 patients receiving 1,557 implants using the minimally invasive hydraulic sinus condensing technique. *J Periodontol* 2005; 76:482-491.
- Butterfield KJ, Bennett J, Gronowicz G, Adams D. Effect of platelet-rich plasma with autogenous bone graft for maxillary sinus augmentation in a rabbit model. *J Oral Maxillofac Surg* 2005; 63:370-376.
- Steigmann M, Garg AK. A comparative study of bilateral sinus lifts performed with platelet-rich plasma alone versus alloplastic graft material reconstituted with blood. *Implant Dent* 2005; 14:261-266.

16. Consolo U, Zaffe D, Bertoldi C, Ceccherelli G. Platelet-rich plasma activity on maxillary sinus floor augmentation by autologous bone. *Clin Oral Implants Res* 2007; 18:252–262.
17. Karabuda C, Ozdemir O, Tosun T, Anil A, Olgaç V. Histological and clinical evaluation of 3 different grafting materials for sinus lifting procedure based on 8 cases. *J Periodontol* 2001; 72:1436–1442.
18. Lundgren S, Andersson S, Gualini F, Sennerby L. Bone reformation with sinus membrane elevation: a new surgical technique for maxillary sinus floor augmentation. *Clin Implant Dent Relat Res* 2004; 6:165–173.