

MINIMALLY INVASIVE ANTRAL MEMBRANE BALLOON ELEVATION IN THE PRESENCE OF ANTRAL SEPTA: A REPORT OF 26 PROCEDURES

Efraim Kfir, DMD; Moshe Goldstein, DMD; Ronen Rafaelov, DMD; Israel Yerushalmi, DMD; Vered Kfir, DMD; Ziv Mazor, DMD; Edo Kaluski, MD

- 1|2|3 Antral septa of the maxillary sinus occurs in approximately one third of patients undergoing posterior maxillary bone augmentation and is considered a relative contraindication for lateral maxillary window (“hinge osteotomy”). We present the results of 26 consecutive cases of patients with septated maxillary sinus who underwent minimally invasive antral membrane balloon elevation (MIAMBE) followed by bone augmentation and implant fixation. After undergoing preprocedural assessment and signing an informed consent, 57 consecutive patients were referred for posterior maxillary bone augmentation. Alveolar crest exposure (via 3-mm osteotomies), MIAMBE, and bone augmentation were followed by implant placement and primary closure (executed at the same sitting). Implant loading was done 6–9 months later. Twenty-six out of 57 (45.6%) patients had significant septa (detected on computed tomography) in the designated augmentation region.
- 4 Twenty-four (92%) concluded the initial procedure successfully. Two patients had membrane tear requiring procedure abortion. Mean procedure time was 48 ± 23 minutes. Incremental bone height consistently exceeded 10 mm, and implant survival of 95.2% was observed at 6–9 months. MIAMBE can be applied to patients in need of posterior maxilla bone augmentation in the presence of septated maxillary sinus with high procedural success, low complication rate, and satisfactory bone augmentation and implant survival. MIAMBE should be an alternative to the currently employed methods of maxillary bone augmentation, especially in the presence of septated maxilla.

Key Words: antral membrane, posterior maxillary implants, bone-augmentation, dental implants, maxillary sinus, sinus lift

Efraim Kfir, DMD, is at a dental clinic in Petah-Tikvah, Israel.

Moshe Goldstein, DMD, is at the Department of Periodontology, Faculty of Dental Medicine, The Hadassah-Hebrew University Medical Center, Jerusalem, Israel.

Ronen Rafaelov, DMD, is at a dental clinic in Sprintzak St, Tel-Aviv, Israel.

Israel Yerushalmi, DMD, is at a dental clinic in Ramat Gan, Israel.

Vered Kfir, DMD, is at a dental clinic in Kupat Holim Clalit (Remez), Rehovot, Israel.

Ziv Mazor, DMD, is at a periodontal clinic, Raánana, Israel.

Edo Kaluski, MD, is at the Department of Cardiology, University Hospital, University of Medicine and Dentistry, Newark, New Jersey. Address correspondence to Dr Kaluski, Director of Invasive Cardiology and Cardiac Catheterization Laboratories University Hospital, University of Medicine and Dentistry of New Jersey, 185 South Orange Ave, MSB I-538, Newark, NJ 07103. (e-mail: ekaluski@gmail.com, kalusked@umdnj.edu)

INTRODUCTION

Bone augmentation of the edentulous posterior maxillary segment has been conventionally addressed by 2 approaches: (1) lateral maxillary window (“hinge osteotomy”) and (2) the “osteotome technique,”¹ which is also called bone added osteotome sinus floor elevation (BAOSFE). The latter method yields modest bone height increments^{2,3}; hence, is not suitable for patients with markedly reduced^{4,5} initial bone height.⁶ Even in the best of hands employing dedicated instrumentation,⁷ BAOSFE can be complicated by membrane perforation and tear.⁸ The lateral maxillary window offers a robust

average implant survival of 91.8% (ranging from 61.7%–100%).⁹ This method suffers from considerable shortcomings, including procedure complications (membrane tear, bleeding, infection, nerve laceration, and sinus obstruction), periprocedural swelling and discomfort, and relative contraindications (sinus convolution septum or narrow sinus and previous sinus surgery). Lateral maxillary window also requires considerable surgical skills, equipment, and time. Antral septa is the most frequently encountered (25%–50%) anatomic relative contraindication for sinus lift surgery. Computed tomography (CT) is more sensitive and specific in detecting and assessing the presence, location, and extent of septated maxillary sinus. The presence of septated maxillary sinus requires alteration of surgical technique and carries a higher complication rate. Minimally invasive antral membrane balloon elevation (MIAMBE)^{10,11} is one of many¹² modifications of the BAOSFE method in which antral membrane elevation is executed via the osteotomy site (of ≤ 3.5 mm) using a dedicated balloon. This manuscript describes a single center experience performing MIAMBE in a subset of patients with anatomically significant maxillary sinus septum.

MATERIALS AND METHODS

Patients

Between 2005 and 2008, 57 consecutive patients with edentulous posterior maxillary segment lacking sufficient bone mass to support implants, were referred for MIAMBE. These patients were part of the multicenter MIAMBE registry, which required adherence to a predefined protocol. Twenty-six patients had a clinically significant septum involving the region requiring augmentation.

Materials

- (1) MIAMBE balloon harboring device (MIAMBE, Netanya, Israel) is a stainless steel tube that connects on its proximal end to the dedicated inflation syringe, and on its distal portion has a screw-in mechanism, which secures the device into the osteotomy site (Figure 1). The single-use balloon is concealed in the distal end until it is inflated with diluted contrast.
- (2) Dedicated "MIAMBE kit" including bone graft injector, osteotome, screw-tap, and a suction device (MIAMBE).
- (3) Coronary angioplasty inflation syringe (Merit Medical, Galway, Ireland) filled with diluted

contrast material (Ultravist 300 by Schering AG, Berlin, Germany).

- (4) Autologous platelet rich fibrin (PRF) obtained by centrifugation of 10 mL divided into 4–8 test tubes and spun for 10 minutes at 2700 rpm.
- (5) Synthetic bone graft (MinerOss, Biohorizons, Birmingham, Ala).
- (6) Autogenic bone collected during drilling by bone filter and bone particles from the tuberosity collected with Ronguer (Stoma, Emmingen-Liptingen, Germany).
- (7) Fisiograft gel (GHIMAS, Casalecchio de Reno, Italy).

Study protocol

Preprocedural CT scan and panoramic and periapical radiographs were used to assess mucosal thickness and pathology, bone height and thickness, sinus structure, and major blood vessels. Patients received a verbal explanation accompanied by an audiovisual presentation regarding the procedure and signed an informed consent.

A preprocedural nonsteroidal anti-inflammatory agent was prescribed. Augmentin (clavulanate potassium), 875 mg twice daily, was initiated 24 hours prior to the procedure. Nitrous oxide sedation and local anesthesia (infiltration of posterior and middle superior alveolar nerve and greater palatine nerve) were performed using Ubistesin 4% (3M ESPE Dental, Seefeld, Germany). To obtain PRF, 40–80 mL of the patient's blood was drawn by venous puncture and processed.

Under local anesthesia, the horizontal full thickness flap (Figure 2a) with palatal bias (to preserve keratinized tissue) was followed by 2 small vertical incisions to expose the alveolar crest (Figure 2b). After drilling depth was determined according to measurements obtained from the CT scan, pilot-drilling (2 mm diameter) was done in the center of the alveolar crest up to 1–2 mm below the sinus floor (Figure 2c and d).

The osteotomy was enlarged (Figure 3a) with the dedicated osteotome (Figure 3b) from 2–2.9 mm (Figure 3c). Bone graft material was injected into the osteotomy, and subsequently, the sinus floor was gently fractured (penetration depth was controlled by adjusting the length of Teflon stoppers of the osteotome). After removing the osteotome, the membrane integrity was assessed (by Valsalva maneuver). Bone graft material was injected again and the screw-tap (Figure 4a) was tapped into the osteotomy 2 mm beyond the sinus floor (Figure 4b).

After screw-tap removal and evaluation of sinus membrane integrity, the metal sleeve of the balloon-

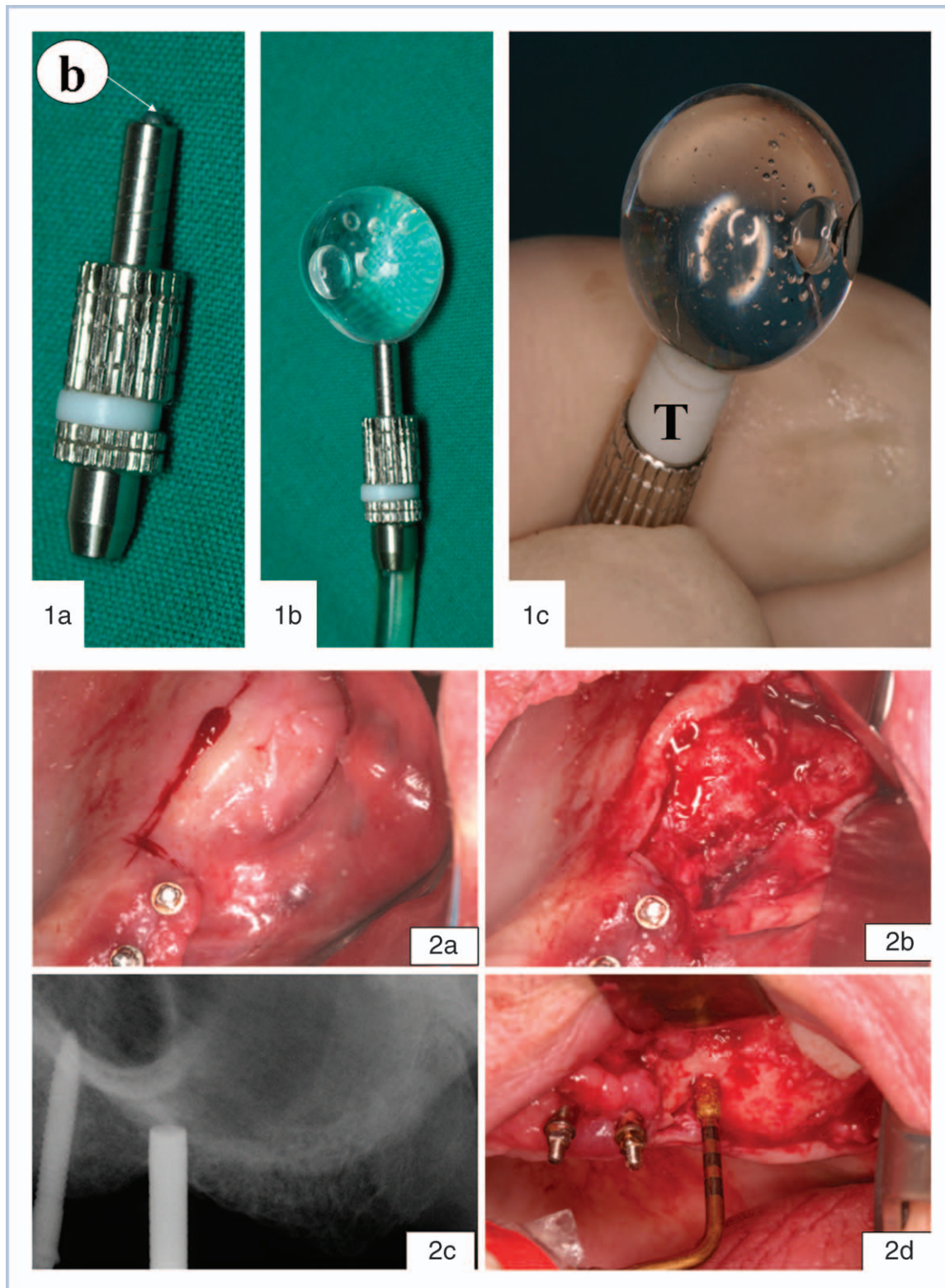
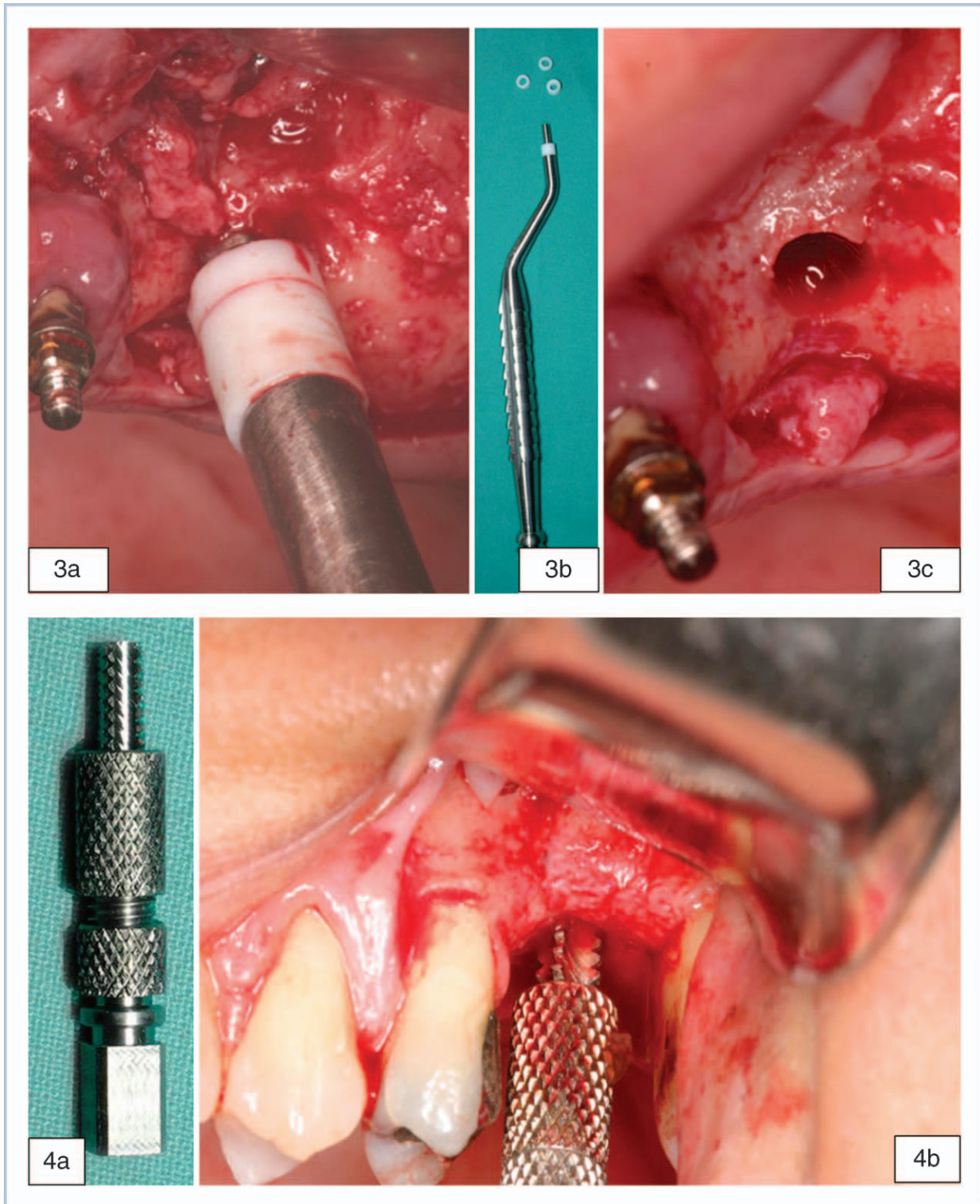
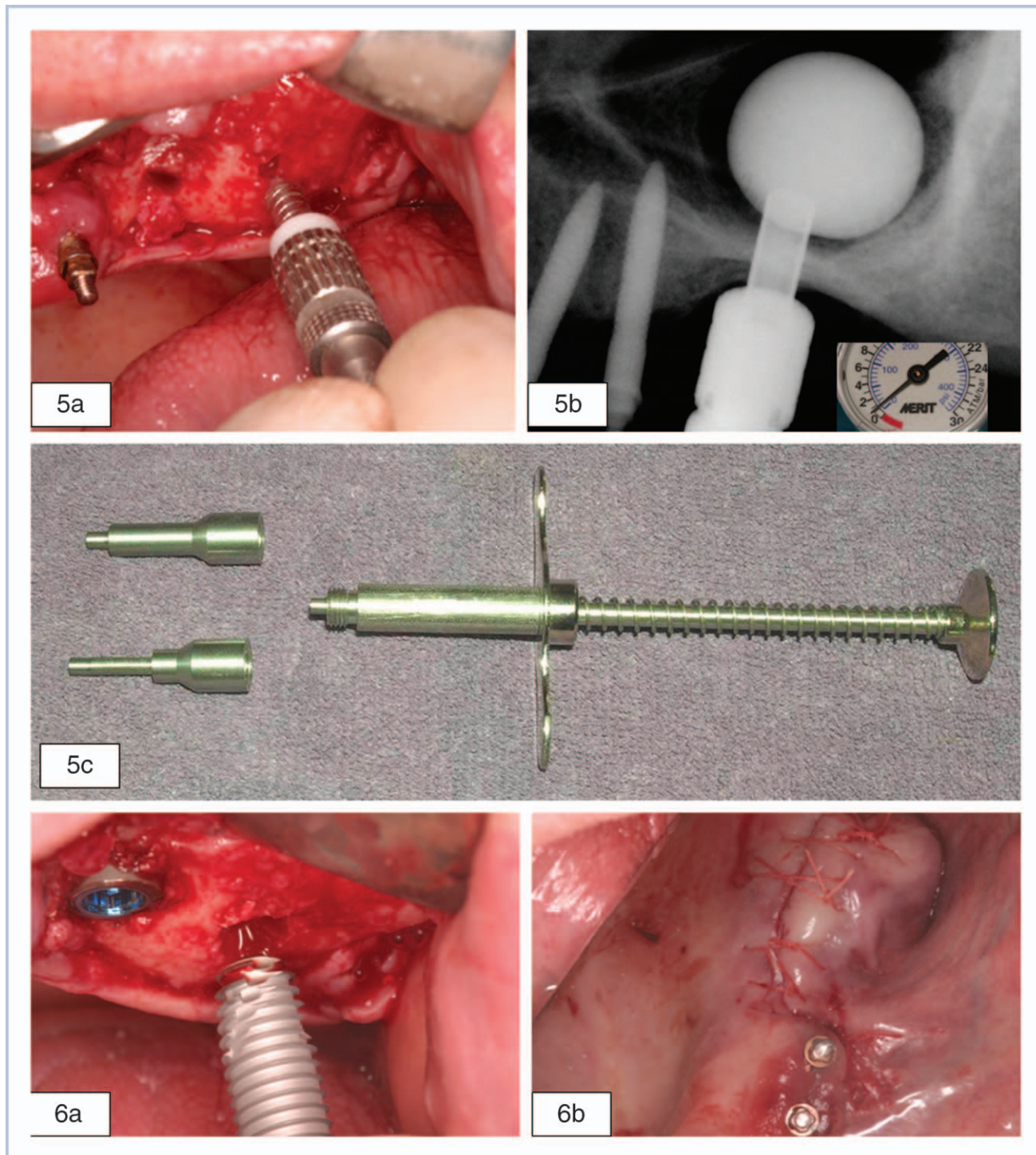


FIGURE 1. Balloon harboring device: when balloon (b) is deflated and concealed (a), during balloon inflation (b), with dedicated Teflon (T) stoppers (c).
FIGURE 2. Horizontal (a) and vertical (b) incisions, and power drilling to obtain initial osteotomy (c and d).



FIGURES 3-4. FIGURE 3. Widening osteotomy (a) with dedicated osteotome (b). FIGURE 4. Screw tap (a) tapped into osteotomy (b).



FIGURES 5-6. FIGURE 5. Balloon harboring device in osteotomy (a) and at low pressure inflation (b), and bone graft injector (c). FIGURE 6. Implant placement (a) and primary closure (b).

harboring device was inserted into the osteotomy 1 mm beyond the sinus floor (Figure 5a). The balloon was inflated slowly with the barometric inflator up to 2 atmospheres (Figure 5b). Once the balloon emerged from the metal sleeve underneath the sinus mem-

brane, the pressure dropped down to 0.5 atmospheres. Subsequently, the balloon was inflated with progressively higher volume of contrast fluid. The balloon inflation and membrane elevation are evaluated by sequential periapical X rays. Once the desired

elevation (usually >10 mm) is obtained, the balloon should be left inflated ≥ 5 minutes to reduce the sinus membrane recoil. Then, the balloon was deflated and removed. The membrane integrity was assessed by direct visualization and examination with the suction syringe and respiratory movement of blood within the osteotomy.

Using a bone graft injector (Figure 5c), a mix of bone substitute (MinerOss), PRF, and autologous bone particles (collected by suction filter during drilling and bone from the tuberosity collected by Ronguer) was injected through the osteotomy underneath the antral membrane followed by implant (3.75–5 mm diameter) placement (Figure 6a) and primary closure (Figure 6b). Implant placement at the same sitting was optional if initial bone height was ≤ 2 mm.

Patients were discharged with ibuprofen, 600 mg (single dose), for pain relief, and Augmentin, 875 mg twice daily for 7 days. Suture removal was executed within 7 days. At 6 months follow-up CT scan and periapical radiographs were performed and prosthetic rehabilitation was initiated 3 weeks after implant exposure.

Study endpoints

This registry's feasibility and efficacy primary endpoint were a successful conclusion of the initial procedure (including ≥ 10 mm antral membrane elevation, bone grafting, and implant fixation when appropriate). The primary safety endpoint was major complications (including severe bleeding, infection, nerve injury, and prolonged [>7 days] disability). Procedure time, implant failure, and bone height at 6 months, were also monitored.

RESULTS

Patients

Between July 2005 and March 2009, 57 patients were referred for the procedure. Twenty-six of these had significant septum in the augmented area. Mean age of patients was 38.1 ± 11.9 years, 7 (26.9%) were smokers, and 12 (46.1%) were male (See Table).

Primary endpoint

Procedural Success

Initial procedural success was accomplished in 24 (92.3%) patients. Two procedures were aborted, due to membrane tear. These patients have successfully undergone MIAMBE 3 months after the initial failed attempt. Four patients had micropuncture of the antral membrane; however, in these cases MIAMBE

	Current Study (n = 26)
Primary procedural success (%)	24 (92%)
Secondary procedural success (%)	26 (100%)
Initial procedural failure (%)	2 (8%)
Membrane microtear	4 (15%)
Initial bone height (mm mean \pm SD)	3.9 ± 2.1
6 months bone height increment (range)	11–18
Number of implants (mean \pm SD)	1.615
Range of implants diameter (mm)	3.75–5
Range of implants length (mm)	13–17.1
Implant survival at >6 months	95.2%
Major complications (procedure abortion)	2 membrane tear
Procedure time (mean \pm SD)	48 ± 23
Implants failure at 6 months (%)	2/42 (4.7%)
Follow in months (mean \pm SD)	11 ± 5

*MIAMBE indicates minimally invasive antral membrane balloon elevation.

was executed successfully, employing a PRF membrane to close the perforation. No other complications were recorded during or after the procedure.

Secondary Endpoints

Procedure time was 48 ± 23 minutes. Structured follow-up for ≥ 12 months was mandated as part of the MIAMBE multicenter registry. Sufficient bone augmentation was documented in all patients and only 2 (4.8%) of 42 implants failed during the follow-up of ≥ 6 months. Patients needed very little medical attention: no patient required additional pain-control medications or medication for swelling alleviation. There were no postprocedural emergency or distress calls. The Table summarizes the results of the current study.

Demonstrative Cases

We submit 2 demonstrative cases that emphasize step by step, technical aspects of the procedure (Figures 7a through i and 8a through e). 7

DISCUSSION

Septum of the maxillary sinus (also called antral septa or Underwood's septa) is a frequent finding affecting approximately one third of edentulous maxillas. In a cadaver study, 39% had bony septa >4 mm; two thirds of these were symmetrical bony septa and three fourths were complete.¹³

Panoramic and periapical radiographs (when compared to CT scan) tend to underestimate the presence of septa especially in the anterior and posterior portion of the maxillary sinus.¹⁴

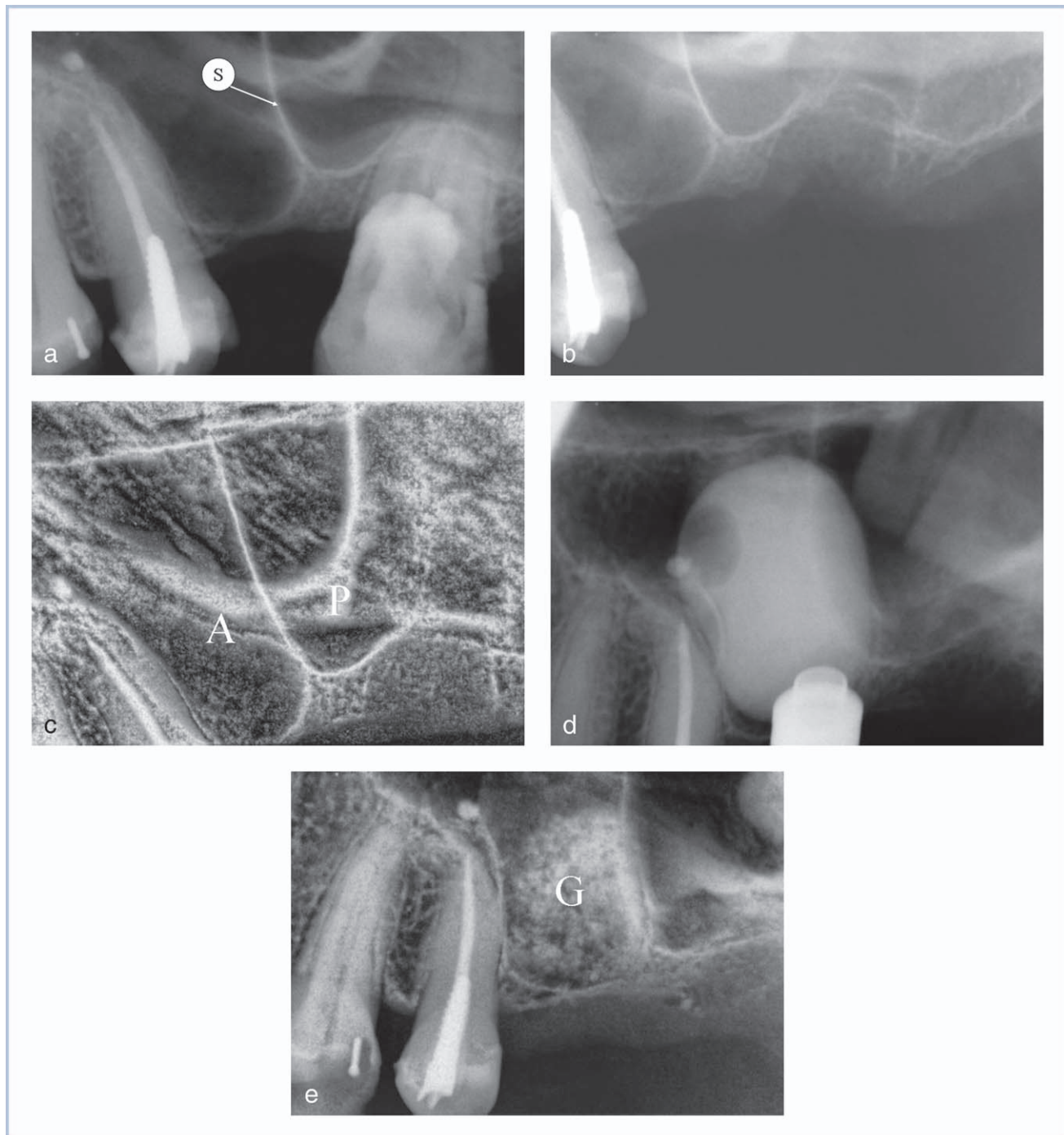


FIGURE 7. Case 1. (a) Pre-extraction radiograph area 26–27, bone height is approximately 1 mm with a developed septum (S). (b) Post extraction in area 27—there is no floor in—only the sinus membrane. (c) Anterior (A) and posterior (P) compartments. (d) MIAMBE first balloon inflation. (e) Bone grafting (G) in the anterior compartment.

In CT scan assessment of the maxillary sinus in 200 subjects,¹⁵ the prevalence of one or more septa per sinus was found to be 26.5% (53/200), 31.76% (27/85), and 22.61% (26/115) in the overall study population, atrophic/edentulous, and nonatrophic/dentate maxillary segments, respectively. The incidence of septa

was somewhat lower (21.58%, of which 39% were bilateral) when panoramic radiographs were employed.¹⁶ Septa may arise in any of the 3 regions of the maxillary sinus irrespective of the degree of edentulism present. Shibli et al¹⁶ suggested that the prevalence of antral septa is unrelated to gender or

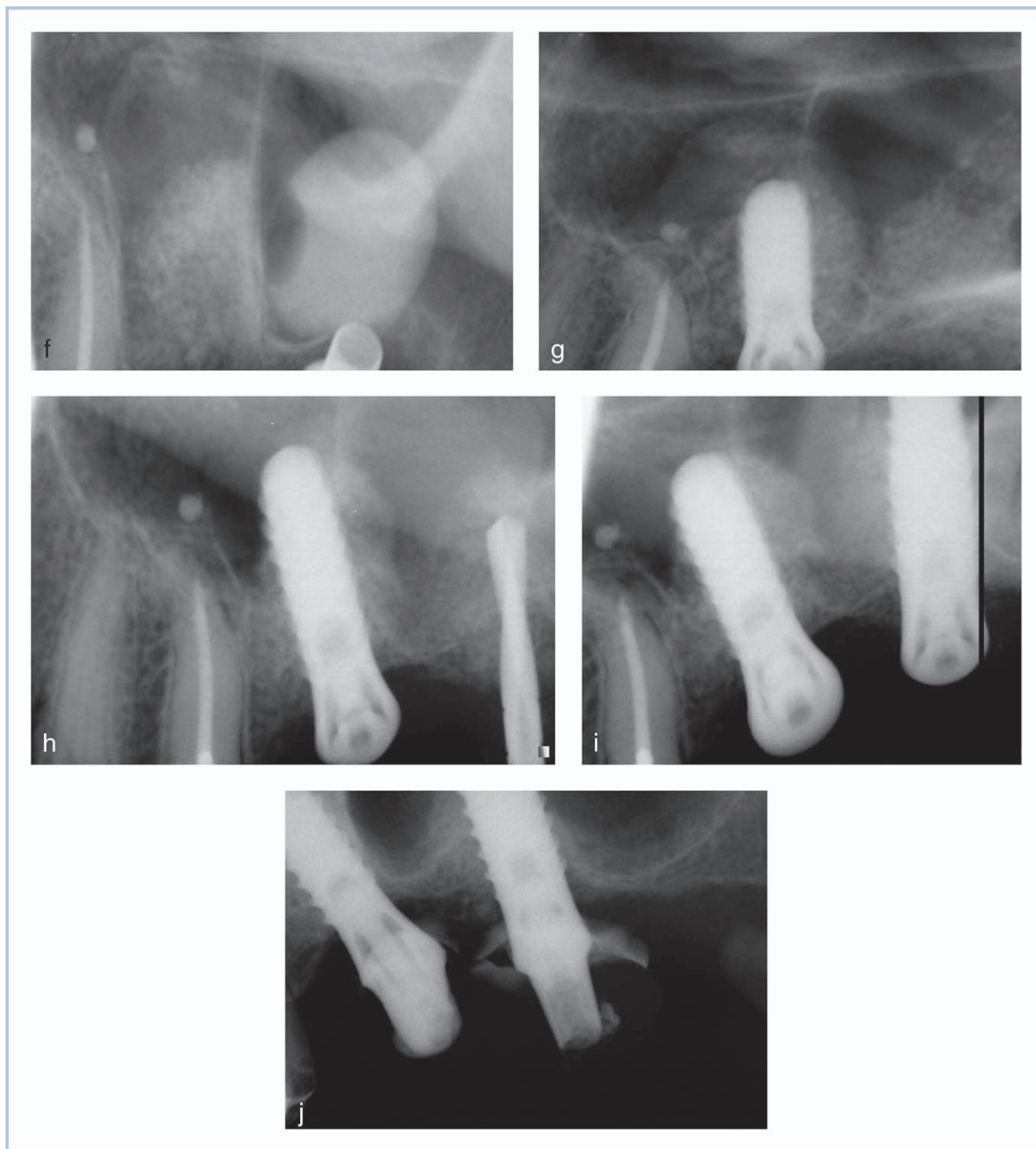


FIGURE 7. Case 1 continued. (f) MIAMBE second balloon inflation. (g) Implant placement in the first compartment. (h) Drilling 9 months later. (i) Second implant placement. (j) Implant rehabilitation 20 months later.

age. Septa are encountered most frequently in region between the second premolar and first molar.¹⁷ In one study,¹⁵ the location was most commonly middle (50.8%) > anterior (25.4%) > posterior (23.7%). The mean septal heights were 1.63 ± 2.44 , 3.55 ± 2.58 ,

and 5.46 ± 3.09 mm in the lateral, middle, and medial areas, respectively. While Shibli¹⁶ confirmed that septa were more prevalent in the middle portion of the sinus, Krennmair et al¹⁸ found antral septa to be more prevalent in the anterior location. Shibli¹⁶ noted that

9

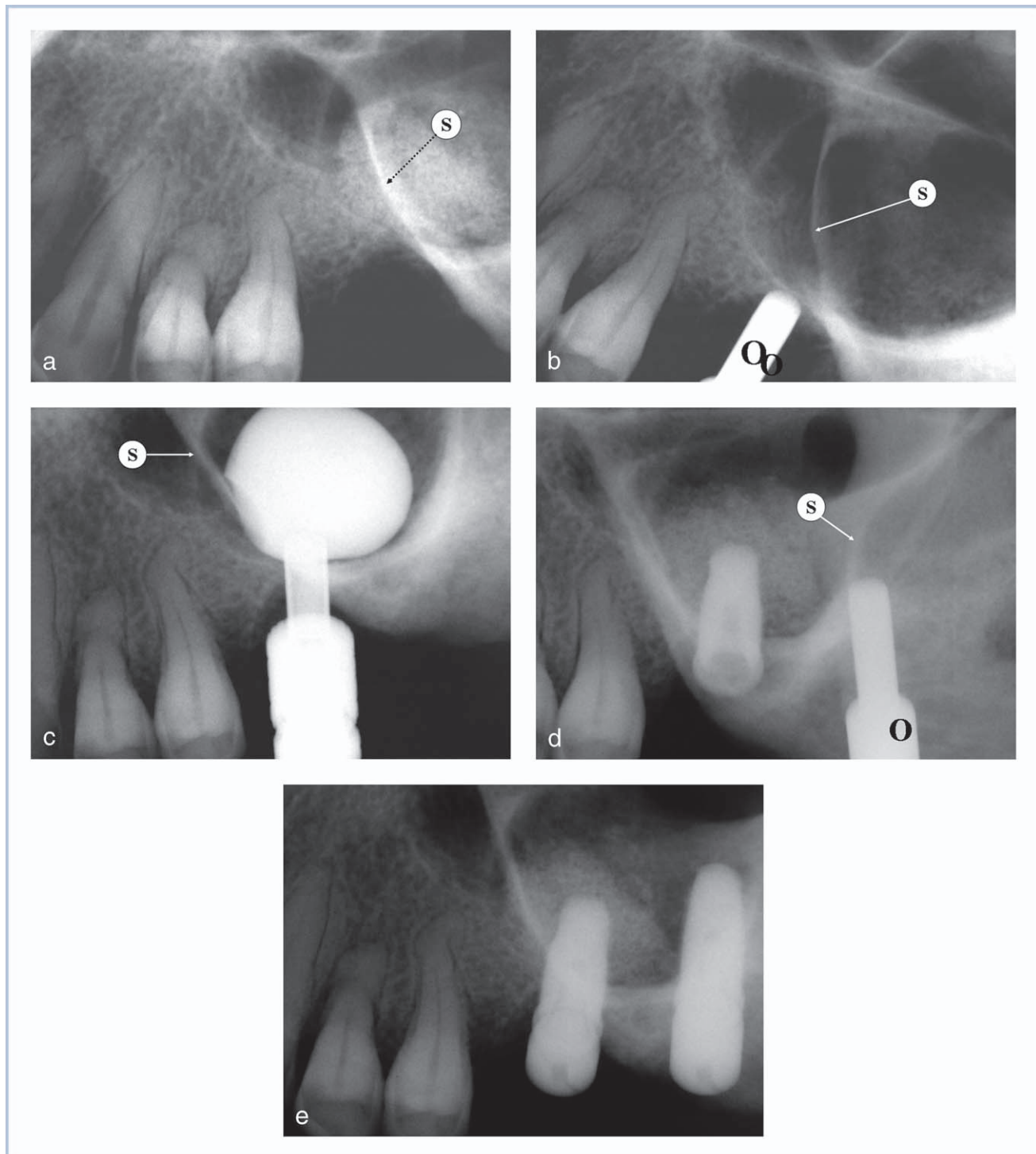


FIGURE 8. Case 2. (a) Preprocedural periapical radiograph: septum (S) noted. (b) Osteotome (O) fracturing the sinus floor. (c) First balloon inflation (MIAMBE) of the anterior compartment. (d) After bone grafting of the anterior compartment and implant placement, osteotomy is enlarged toward the posterior compartment. (e) After MIAMBE and bone grafting of the posterior compartment implant placement.

septal height varied greatly within each area (lateral mean 3.54 ± 3.35 mm [range 0–15.7 mm], middle mean 5.89 ± 3.14 mm [range 0–17.3 mm], and medial mean of 7.59 ± 3.76 mm [range 0–20.6 mm]).

Although the surgical literature does describe in great detail the impact of antral septa on the short- and long-term results of lateral window, this anatomic finding seems to significantly complicate sinus lift

surgery and compromise its results. In certain series, sinus floor elevation surgery was hindered by antral septa in 48% of the cases.¹⁹ Membrane tear is a common complication of sinus floor elevation procedures occurring in 10%–60%¹⁹ of the cases. The presence of septa increases the likelihood of membrane tear, procedural failure, and long-term complication. The surgeon encountering an antral septa is required to modify the conventional surgical method. Tidwell²⁰ subdivided the bony wall into an anterior and posterior part of the hinge door and inverted both trapdoors. Zijderveld¹⁹ recommended following the contour of the sinus floor by making a W-shaped preparation in smaller septa or 2 separate doors.

¹⁰ Others²¹ suggested an antrostomy approach. Whatever surgical solution is adopted for the individual case, it almost uniformly requires extending the surgical window, prolonging the procedure time and results in higher likelihood of encountering membrane tear and procedural failure.

¹¹ This registry supports the former notion that MIAMBE, a minimally invasive, single sitting procedure of maxillary bone augmentation and implant placement can be executed safely in the presence of antral septa. The procedural goals of this new method were met: initial procedural success of 92.3%, with an ultimate procedural success of 100% (when second MIAMBE attempts were accounted for) in this nonselective all-inclusive cohort. Although microtears were observed in 4 patients (15%), these events were viewed by the investigators as more of a nuisance than a complication. The microtears were easily sealed by PRF and in a worst-case scenario would have required an additional osteotomy site. These events had no meaningful effect on procedural outcome and were not associated with suboptimal augmentation or implant durability. Although the mean preprocedural bone height in this series was 3.9 mm, the authors are convinced that there is no minimal bone height required for this procedure. MIAMBE of atrophic (“eggshell”) maxillary bone results in a similar success rate and ultimate bone growth as the less diseased maxillas.

¹² The current registry incorporated a relatively high percentage of septated maxillary sinus and other challenging sinus and periodontal pathology because during these years these cases were referred from all over Israel for MIAMBE after the surgical option was declined.

The procedure consistently yielded satisfactory bone augmentation, which resulted in an impressive (95.3%) implant survival at 6–8 months. On the physician end: this procedure is highly successful, without excessive costs and labor-intensive postprocedural management issues. On the patient side: this

procedure eliminates the complications (which is especially high among antral septa patients), discomfort, and disfigurement associated with traditional hinge osteotomy, and may abbreviate the time to implant exposure and functionality. These “patient issues” are probably the major patient-related barriers of more widespread use of implants in the posterior maxillary segment.

CONCLUSIONS

MIAMBE appears to carry a high procedural success rate and very acceptable complication rate in patients with antral septa, which account for one third of the patients requiring posterior maxillary bone augmentation. On the patient end, the procedure is truly minimally invasive and complication-free, is associated with only mild discomfort, and consistently delivers early functional implants. On the physician end, it appears from this registry that MIAMBE is safe, trouble-free, and less time- and cost-consuming than lateral window.

REFERENCES

1. Summers RB. Sinus floor elevation with osteotomes. *J Esthet Dent.* 1998;10:164–171.
2. Rosen PS, Summers R, Mellado JR, et al. The bone-added osteotome sinus floor elevation technique: multicenter retrospective report of consecutively treated patients. *Int J Oral Maxillofac Implants.* 1999;14(6):853–858.
3. Emmerich D, Att W, Stappert C. Sinus floor elevation using osteotomes: a systematic review and meta-analysis. *J Periodontol.* 2005;76(8):1237–1251.
4. Fugazzotto PA. Augmentation of the posterior maxilla: a proposed hierarchy of treatment selection. *J Periodontol.* 2003;74(11):1682–1691.
5. Toffler M. Staged sinus augmentation using a crestal core elevation procedure and modified osteotomes to minimize membrane perforation. *Pract Proced Aesthet Dent.* 2002;14:767–774.
6. Nkenke E, Schlegel A, Schultze-Mosgau S, Neukam FW, Wiltfang J. The endoscopically controlled osteotome sinus floor elevation: a preliminary prospective study. *Int J Oral Maxillofac Implants.* 2002;17:557–566.
7. Nkenke E, Schlegel A, Schultze-Mosgau S, Neukam FW, Wiltfang J. The endoscopically controlled osteotome sinus floor elevation: a preliminary prospective study. *Int J Oral Maxillofac Implants.* 2002;17:557–566.
8. Berengo M, Sivoletta S, Majzoub Z, Cordioli G. Endoscopic evaluation of the bone-added osteotome sinus floor elevation procedure. *Int J Oral Maxillofac Surg.* 2004;33:189–194.
9. Wallace SS, Fromm SJ. Effect of maxillary sinus augmentation on the survival of endosseous dental implants. A systematic review. *Ann Periodontol.* 2003;8:328–343.
10. Kfir E, Kfir V, Mijiritsky E, Rafaeloff R, Kaluski E. Minimally invasive antral membrane balloon elevation followed by maxillary bone augmentation and implant fixation. *J Oral Implantol.* 2006;32(1):26–33.

11. Kfir E, Kfir V, Eliav E, Kaluski E. Minimally invasive antral membrane balloon elevation: report of 36 procedures. *J Periodontol.* 2007;78(10):2032–2035.
12. Chen L, Cha J. An 8-year retrospective study: 1,100 patients receiving 1,557 implants using the minimally invasive hydraulic sinus condensing technique. *J Periodontol.* 2005;76(3):482–491.
13. Ella B, Noble Rda C, Lauerjat Y, et al. Septa within the sinus: effect on elevation of the sinus floor. *Br J Oral Maxillofac Surg.* 2008;46(6):464–467.
14. González-Santana H, Peñarocha-Diago M, Guarinos-Carbó J, Sorní-Bröker M. A study of the septa in the maxillary sinuses and the subantral alveolar processes in 30 patients. *J Oral Implantol.* 2007;33(6):340–343.
15. Kim MJ, Jung UW, Kim CS, et al. Maxillary sinus septa: prevalence, height, location, and morphology. A reformatted computed tomography scan analysis. *J Periodontol.* 2006;77(5):903–908.
16. Shibli JA, Faveri M, Ferrari DS, et al. Prevalence of maxillary sinus septa in 1024 subjects with edentulous upper jaws: a retrospective study. *J Oral Implantol.* 2007;33(5):293–296.
17. Ulm CW, Solar P, Krennmair G, Matejka M, Watzek G. Incidence and suggested surgical management of septa in sinus-lift procedures. *Int J Oral Maxillofac Implants.* 1995;10(4):462–465.
18. Krennmair G, Ulm C, Lugmayr H. Maxillary sinus septa: incidence, morphology and clinical implications. *J Craniomaxillofac Surg.* 1997;25(5):261–265.
19. Zijderveld SA, van den Bergh JP, Schulten EA, ten Bruggenkate CM. Anatomical and surgical findings and complications in 100 consecutive maxillary sinus floor elevation procedures. *J Oral Maxillofac Surg.* 2008;66(7):1426–1438.
20. Tidwell JK, Blijdorp PA, Stoelinga PJ, Brouns JB, Hinderks F. Composite grafting of the maxillary sinus for placement of endosteal implants. A preliminary report of 48 patients. *Int J Oral Maxillofac Surg.* 1992;21(4):204–209.
21. Shlomi B, Horowitz I, Kahn A, Dobriyan A, Chaushu G. The effect of sinus membrane perforation and repair with Lambone on the outcome of maxillary sinus floor augmentation: a radiographic assessment. *Int J Oral Maxillofac Implants.* 2004;19(4):559–562.

Authors QueriesJournal: **Journal of Oral Implantology**Paper: **orim-35-05-11**Title: **MINIMALLY INVASIVE ANTRAL MEMBRANE BALLOON ELEVATION IN THE PRESENCE OF ANTRAL SEPTA: A REPORT OF 26 PROCEDURES**

Dear Author

During the preparation of your manuscript for publication, the questions listed below have arisen. Please attend to these matters and return this form with your proof. Many thanks for your assistance

Query Reference	Query	Remarks
1	Author: This article has been lightly edited for grammar, style, and usage. Please compare it with your original document and make changes on these pages. Please limit your corrections to substantive changes that affect meaning. If no change is required in response to a question, please write "OK as set" in the margin. Copy editor.	
2	Author: Structured abstract revised to one paragraph. Please confirm. Copy editor.	
3	Author: Please review affiliations. Add information, eg, "is in private practice at a dental clinic..."? Copy editor.	
4	Author: In sentence beginning with "Twenty-four (92%) concluded," add denominator of 26 to clarify 92%? Copy editor.	
5	Author: In Figure captions, use of lower and upper case alpha seems confusing. Eg, Osteotome is shown with upper case O, and balloon, lower case b. Different phases are shown in upper case in Figs 2 and 3 and lower case in Figs 7 and 8. Format like terms similarly? Copy editor.	

6	Author: Figure 3C is not included in Figure 3 caption. Please add to caption or remove from text? Copy editor.	
7	Author: The steps in the captions for Figures 7 and 8 are in lower case. Text was changed to lower case. Please confirm. Copy editor.	
8	Author: In paragraph beginning with "In CT scan assessment," show all percentages to 1 or 2 decimal points? Copy editor.	
9	Author: In sentence beginning with "In one study,[15]" rephrase to avoid use of greater than symbols for easier readability? Copy editor.	
10	Author: In sentence beginning with "Others[21]," revise perhaps to "Shlomi et al[21]"? Copy editor.	
11	Author: Reword sentence beginning with "Whatever surgical solution ..."? Perhaps: "Whatever surgical solution is adopted for the individual case, it almost uniformly requires extending the surgical window, which prolongs the procedure time and increases the likelihood of membrane tear and procedural failure."? Copy editor.	
12	Author: Revise sentence beginning with "MIAMBE of atrophic..."? Perhaps "MIAMBE of atrophic ("eggshell") maxillary bone has a success rate and ultimate bone growth that is similar to that of less diseased maxillas.<Copy editor.	
13	Author: Last sentence of Conclusion ended rather abruptly. Were words dropped? Copy editor.	

14	Author: Please review issue numbers cited in Ref #2 and below. Please include issue number only if each issue in volume begins with page 1. Copy editor.	
15	Author: References #6 and #7 are identical. Remove duplicate and renumber references in list and text? Copy editor.	
16	Editor: Are rpm ok for centrifugation or are gravities headed?? PR	